

Macrophage activation syndrome: A nearly fatal presentation, and review of diagnosis and treatment guidelines

Luis W. Dominguez, Valentin D. Marian

ABSTRACT

Introduction: Macrophage activation syndrome (MAS) is a rare but life-threatening systemic inflammatory complication, usually arising from superimposed viral infections or flares of underlying rheumatological conditions. It is characterized by an uncontrolled immune response, involving the expansion of T-Cells, Macrophages, and the hypersecretion of pro-inflammatory cytokines. The pathophysiology of this disease is not fully understood, and the diagnostic criteria have been debated. In 2016, an international panel of experts released new guidelines for the classification criteria of MAS, with greater sensitivity, specificity, and laboratory guidelines. Our case provides support for these new guidelines, and is possibly the first published after their release. Furthermore, treatment using glucocorticoids and alternative immunosuppressants is also reviewed. **Case Report:** A 33-year-old Hispanic male without significant history presented with an unremitting fever for five days, associated with myalgias, fatigue, night sweats, and a rash. Upon admission, he was tachycardic, hypotensive and febrile at 103°F (39.4°C). Physical examination revealed

a diffuse, non-blanching, maculopapular rash sparing the face, palms and soles. Labs revealed pancytopenia, transaminitis, elevated ferritin, and low fibrinogen. He was started on empiric antibiotics. Blood cultures were drawn and returned negative, yet he continued to spike fevers. On 4th day, he suffered acute respiratory distress syndrome (ARDS), requiring mechanical ventilation. He was transferred to the intensive care unit (ICU) where he continued to deteriorate. Given the persistent fever, pancytopenia, transaminitis, low fibrinogen and elevated ferritin, MAS was considered, based on recent classification criteria. He was started on high-dose methylprednisolone. He rapidly recovered, and was extubated within 24 hours and discharged later that week. **Conclusion:** Macrophage activation syndrome is a rare condition with a debated definition, and a mortality rate of up to 30%. As a result, it remains a diagnostic challenge. This case supports the new 2016 guidelines and confirms methylprednisolone as a first-line treatment. Furthermore, MAS seems to have occurred in the absence of underlying rheumatological disease.

Keywords: Adult still's disease, Diagnostic criteria for macrophage activation syndrome, Macrophage activation syndrome (MAS)

Luis W. Dominguez¹, Valentin D. Marian²

Affiliations: ¹Department of Internal Medicine, Jersey City Medical Center; ²Department of Rheumatology and Assistant Program Director, Jersey City Medical Center Jersey City Medical Center, Jersey City NJ, USA.

Corresponding Author: Luis W. Dominguez MD, MPH. Department of Internal, Medicine, Jersey City Medical Center, 355 Grand St. Jersey City, NJ. 07302. USA; Email: L.W.Dominguez@gmail.com

Received: 01 June 2017

Accepted: 22 June 2017

Published: 19 July 2017

How to cite this article

Dominguez LW, Marian VD. Macrophage activation syndrome: A nearly fatal presentation, and review of diagnosis and treatment guidelines. J Case Rep Images Orthop Rheum 2017;2:12–19.

Article ID: 100006Z14LD2017

doi:10.5348/Z14-2017-6-CR-3

INTRODUCTION

Macrophage activation syndrome (MAS) is an auto-inflammatory phenomenon. An immunogenic trigger over-activates macrophages, resulting in an uncontrolled release of cytokines, and phagocytosis of the body's own cell lines. While most common in pediatrics [1], it has been documented in adults as well. This disease is most prevalent in patients with preexisting rheumatological conditions, especially systemic juvenile idiopathic arthritis (sJIA/pediatric Still's disease), systemic lupus erythematosus (SLE), and adult-onset Still's disease (AOSD) [2]. Due to significant clinical, laboratory and pathophysiological overlap, the taxonomy of AOSD, hemophagocytic lymphohistiocytosis (HLH) and MAS is unclear, and the classification criteria for MAS have been debated. An expert working-group released new classification criteria in 2016, focusing on the presence of (1) a fever PLUS (2) ferritin levels >684 ng/ml, and any two of the following:

- Platelets $\leq 181 \times 10^9/L$
- Triglycerides $> 156 \text{ mg/dL}$
- Fibrinogen $\leq 360 \text{ mg/dL}$
- Aspartate aminotransferase $> 48 \text{ units/L}$ [3]

We present a case of macrophage activation syndrome in the absence of known rheumatologic, immunologic or oncologic disease, most likely triggered by a viral infection, which became life-threatening, and quickly resolved with high-dose corticosteroids. Clinical and laboratory findings in our patient support the diagnosis of MAS, and the new 2016 criteria.

CASE REPORT

A 33-year-old Hispanic male without a significant medical history presented with a fever for five days. The fever was constant, peaking at 103°F (39.4°C). It was preceded by a sore throat, and associated with fatigue, myalgias, and night sweats. The day of admission, the patient broke out in a maculopapular rash while taking a shower. The rash covered his whole body, while sparing the face, palms and soles. Review of symptoms revealed the recent commencement of Depakote for migraines. He reported frequent travel between New Jersey and Connecticut (as a truck driver), multiple tattoos (the last received two years prior), and a sick contact at work with flu-like symptoms. The patient reported allergies to peanuts, penicillin and shellfish. His surgical history was significant for an appendectomy, tonsillectomy, and adenoidectomy. Family and social history were non-contributory, except as mentioned.

In the emergency room, the patient had a fever of 103°F (39.4°C) and was tachycardic at 112 bpm. His blood pressure was 98/55 with normal respiration and saturation. Physical examination revealed a fit young man with multiple tattoos. He had bilateral conjunctival injection, oropharyngeal erythema and a few red, non-vesicular papules on his soft palate. He had no lymphadenopathy. Heart and lung examinations were within normal limits. His abdomen was significant for hepatomegaly. His skin bore a fine, maculopapular, non-blanching rash that spared his face, palms and soles (Figure 1).

His initial labs showed pancytopenia, with a white count of $1.8 \times 10^9/L$, hemoglobin of 12.3 g/dL, and a platelet count of $89 \times 10^9/L$. His liver enzymes were elevated with an alanine aminotransferase (ALT) of 391 U/L, aspartate aminotransferase (AST) of 463 U/L, and a total bilirubin of 7.3 mg/dL, with direct bilirubin 6.6 mg/dL. International normalized ratio (INR) was 1.2 and his C-reactive protein (CRP) was 26 mg/L. His chest X-ray, (Figure 2) and urine analysis were clear.

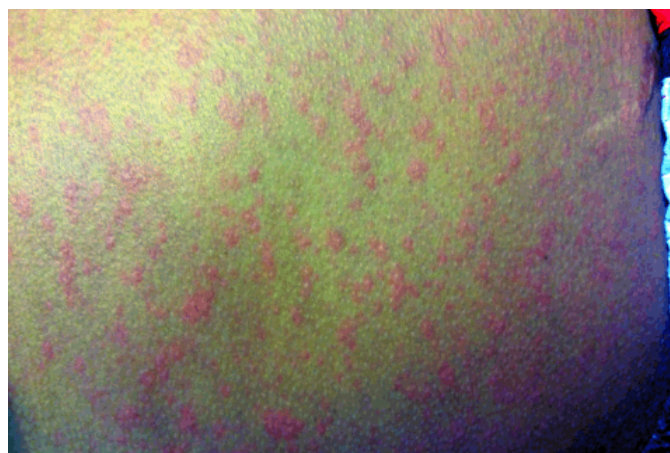

Figure 1: Maculo-papular, non-blanching rash present upon admission.

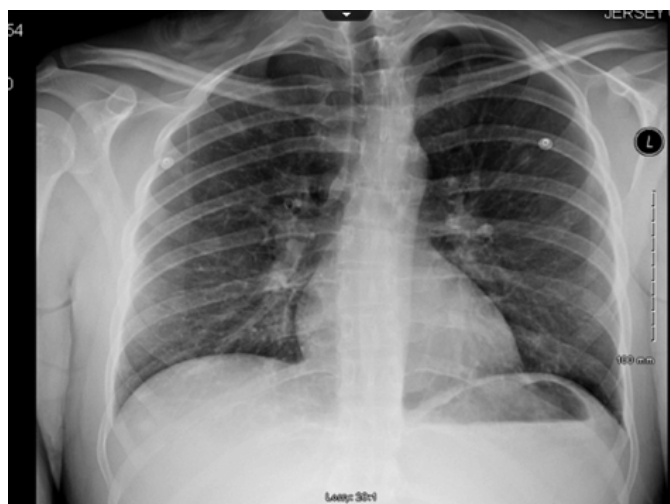


Figure 2: Chest X-ray upon presentation.

Rapid HIV test was negative. Cultures and viral titers were drawn for pathogens which could have disseminated, including viral hepatitis, Epstein–Barr, West Nile, parvovirus, *Mycoplasma*, *Neisseria*, *Rickettsia* and Lyme. The patient was then started on vancomycin and cefepime. Depakote levels were within normal limits.

Over the next 24 hours, the rash resolved. However, his fever continued to spike. His hemoglobin, leukocyte, and platelet counts remained depressed over the next few days. Blood, sputum and urine cultures were returned negative. Viral hepatitis panel was negative. A repeat Chest X-ray on day-4 showed bi-basilar infiltrates. A follow-up computed tomography (CT) scan of the chest confirmed bi-basilar consolidation and pleural effusions.

The patient continued to deteriorate. Four days after admission, he suffered hypoxemic respiratory failure with a heart rate of 140 and temperature of 103°F. Chest X-ray and oxygenation parameters were consistent with adult respiratory distress syndrome (ARDS).

Immuno-assays for viral and atypical bacterial triggers showed IgG positivity for West Nile virus, Epstein-Barr, and *mycoplasma*, but no IgM activity. A bone marrow biopsy was preformed, and returned negative for any significant abnormalities or infectious etiologies. D-dimer was elevated at 8.4 $\mu\text{g}/\text{mL}$, but a peripheral smear was negative for schistocytes. An autoimmune process was proposed, however, his serum was negative for anti-nuclear antibodies or rheumatoid factor. As his ferritin was high (1640 ng/mL) and fibrinogen was low (259 mg/dL), MAS was considered and he was started on methylprednisolone 125 mg IV twice daily.

Within 24 hours, the patient's respiratory status dramatically improved and he was extubated. Chest X-ray before (Figure 3) and after intubation (Figure 4) are shown. He was discharged after five days, in good health and spirits.

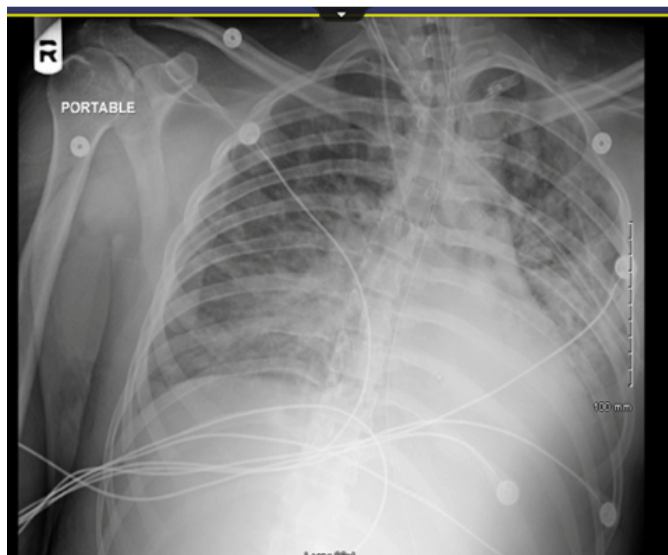


Figure 4: Chest X-ray less than 24 hours after administration of methylprednisolone.

DISCUSSION

Workup

The presentation of an unremitting fever, elevated ferritin, thrombocytopenia, hypofibrinogenemia and transaminitis, fits the 2016 MAS classification criteria discussed below. Infections are known to precipitate MAS [3], and this patient was not improving with conventional therapy. While not definitive, his condition reversed with methylprednisolone, supporting suspicion of an auto-inflammatory process. What does not fit with typical MAS, is the lack of a preexisting rheumatological condition, congenital immunodeficiency or malignancy. The vast majority of MAS cases are tightly associated with significant comorbidities such as sJIA, SLE, or AOSD [4].

Etiology

Macrophage activation syndrome is a disorder in which macrophages mistake healthy tissue for pathogens, become hyperactive, release inflammatory cytokines and consume the body's own cells [2]. Macrophage activation syndrome is usually considered a complication of an underlying rheumatological disease [4]. Autophagocytosis and unbridled systemic inflammation results in multi-organ damage [2].

Macrophage activation syndrome is far more common in pediatrics [1], with data coming from multi-center children's hospitals, usually with fewer than 100 patients. There are documented, but even fewer, cases reported in adults.

Looking across populations, MAS is associated with four predispositions:

- rheumatological conditions (most common),
- immunological deficiencies (usually congenital),
- malignancies, and
- infections [2] (Table 1)

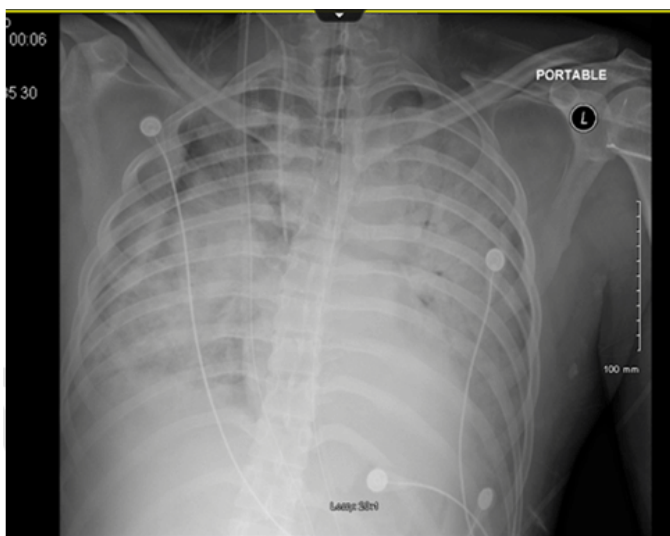


Figure 3: Chest X-ray in severe acute respiratory distress syndrome, before treatment with methylprednisolone.

In children, MAS is most commonly associated with sJIA [2]. Pediatric SLE and Kawasaki’s disease are the second-most commonly associated comorbidities [4]. One small study found while only 25% of sJIA patients had clinical symptoms of MAS, 53% had subclinical features [5]. In adults, MAS is most commonly associated with AOSD and SLE [3]. In a recent meta-analysis, Bae et al. [6] found that 19.3% of adults with Still’s Disease develop some signs of macrophage activation or hemophagocytosis. This lends support to the notion that AOSD and MAS lay on the same pathological spectrum.

Of the immunologic deficiencies, PRF1 mutations resulting in dysfunctional perforin channels are most commonly associated with MAS. Without functional perforin channels, cytotoxic T cells are unable to degranulate, inhibiting cell-to-cell toxicity [7]. Macrophage activation syndrome is also associated with conditions such as Chediak–Higashi syndrome, and chronic granulomatous disease [8]. Acquired immunologic deficiencies such as HIV and organ transplant recipients are also at increased risk for MAS [9].

Macrophage activation syndrome has also been associated with malignancies, particularly lymphoma and leukemia [9]. With regards to infection, many vectors

have been documented, from CMV to HSV and HIV [7]. Epstein-Barr virus is the most commonly associated infectious precipitant [7]. Malignancies and infections often act as triggers for fulminant MAS in patients especially with pre-existing rheumatological conditions.

Taxonomy/Areas of debate

Before continuing, we should remark on areas of debate with the taxonomy. There is a category of pathologies centering on monocyte dysfunction called histiocytic disorders. They include Langerhans histiocytosis, familial hemophagocytic lymphohistiocytosis, acquired/reactive Hemophagocytic Lymphohistiocytosis (aHLH), and MAS [7]. The latter three diseases are pathophysiologically connected [2, 10]. They all include dysfunctional perforin channels, cell to cell cytotoxicity, and NK cell activity [10]. Thus, similarity between MAS and HLH subtypes is widely recognized [2]. The debate lies in whether these diseases are distinct entities or different variations on the same pathology. While some have proposed that MAS and HLH are the same [11], others have posited that MAS is the more severe form or complication of HLH [12]. A third set of investigators suggested that each different receptor mutation results in a clinically distinct disease [4]. It is outside this paper’s scope to investigate further.

Table 1: Macrophage activation syndrome (MAS) and hemophagocytic lymphohistiocytosis (HLH) antecedents and presentation. Made from the combination of results reported the 2016 MAS working group 2 and two HLH reviews.13,20 These are not diagnostic criteria, but rather a table of commonly found associations, clinical and laboratory findings, intended to guide physicians in suspecting a hemophagocytic syndrome

| Associations | | Presentation | |
|---------------------------|-------------------------------|--------------------------------|-------------------------|
| Infectious | | Clinical (% prevalence) | |
| | Epstein–Barr Virus | | Fever 93% |
| | Cytomegalovirus | | Hepatomegaly 68–95% |
| | Herpes Simplex Virus | | Splenomegaly 53–69% |
| | Human Immunodeficiency Virus | | Lymphadenopathy 33–48% |
| Rheumatological | | | CNS deficits 33–40% |
| | Still’s Disease | | Rash 31% |
| | Rheumatoid Arthritis | | Respiratory 27–42% |
| | Systemic Lupus Erythematosus | | Renal |
| Immunodeficiencies | | | Cardiac |
| | Chediak-Higashi | Laboratory | Pancytopenia |
| | Chronic Granulomatous Disease | | Transaminitis |
| | Perforin-1 Mutation | | ↑ Triglycerides |
| | Human Immunodeficiency Virus | | ↑ Ferritin |
| | | | ↑ Fibrinogen |
| | | | Hypercoagulability |
| | | | ↑ Lactate dehydrogenase |
| | | | ↑ D-Dimer |
| | | | ↑ Na |
| | | | Hemophagocytosis |

Given the clinical overlap, these authors agree that HLH and MAS fall on the same spectrum of disease. Variability in treatment guidelines [13], thus seem likely a function of incomplete understanding.

Given the clinical overlap between AOSD and MAS, it has been suggested that MAS may simply be the more severe form [6, 14]. It seems possible then, that AOSD, HLH and MAS may all fall on the same clinical spectrum, with MAS being the most serious manifestation.

Pathophysiology

The development of MAS hinges on dysfunctional cytotoxic and cytolytic activity of NK cells and CD8 T-lymphocytes [2]. Recall that CD8 and NK cells are also responsible for down-regulating activated macrophages [15]. Severe immune-dysfunction is evidenced by the observation that patients with MAS are highly susceptible to infections [16].

Three mechanisms of pathology have been proposed. First, defective lysis of infected cells allow antigens to persist, resulting in the unrelenting activation of macrophages and release of inflammatory cytokines [15], including interferon (IFN- γ), tumor necrosis factor (TNF- α), interleukins (IL-6 & IL-10), and macrophage-colony-stimulating factor (M-CSF) [2]. Second, as NK and CD8 cells are responsible for auto-regulation, the inability to “turn-off” activated lymphocytes could result in progressive inflammation [4, 17–19]. Third, overactive macrophages lose their ability to distinguish ‘self’ from ‘non-self,’ resulting in phagocytosis of vital cell lines, including erythrocytes and platelets [4, 17, 18].

Clinical presentation

Given the rarity of this disease, most research has focused on small cohorts of children with sJIA or SLE. Given the overlap between MAS and HLH, to provide more power, the following section will combine data on MAS and HLH.

Most MAS/HLH patients present with a protracted fever (93% of cases) [20], hepatomegaly (95%), lymphadenopathy (33%), neurologic sequelae (from seizures to altered mental status-33%), and rashes, usually petechial and/or non-blanching (31%) [21]. Forty-two percent of patients reported pulmonary involvement, often resulting in respiratory distress or ARDS [22]. This clinical presentation is loosely replicated by the 2016 work-group on MAS classification [3], with fever (93%), hepatomegaly (68%), splenomegaly(53%) and pulmonary involvement in 27% of cases.

On laboratory studies, 80% of MAS/HLH patients present with bi-cytopenia, usually of platelets and erythrocytes [21]. Transaminitis is found in 50–90% of patients [23]. Lactate dehydrogenase (LDH) is elevated in 85% of patients [24] with a median of 1560 U/L [3] and 68% of patients have elevated triglycerides [25] with a mean of 267mg/dL [3].

Hyperferritinemia is the hallmark, with median ferritin levels of 9094 ng/mL [3]. Note however that there is wide variability in ferritin levels. One review found 93% of cases having ferritin levels greater than 500ng/mL, 42% had levels higher than 5000 ng/mL, and 25% had levels above 10,000 ng/mL [21]. In other words, while very high ferritin is indicative, almost half of MAS patients have ferritin levels below 5000 ng/mL. Accordingly the new 2016 diagnostic criteria suggest 684ng/mL as a classification threshold [3].

Hemophagocytosis is a classic, yet non-definitive marker. To find phagocytized blood cells, multiple biopsies or aspirations are often required, as the presence of phagocytic macrophages changes over the disease course [26]. As a result, positive histology is reported in 25–100% of cases [27]. Accordingly, biopsy is neither sensitive nor specific enough to be pathognomonic [3, 6, 26].

Diagnostic criteria

There have been multiple working groups attempting to define HLH, particularly in 2004 [13] and the Filipovich modification in 2009 [28]. There had been no such attempt to separate out MAS until last year. In 2016, and international panel of 28 experts created classification criteria based upon a review of 428 cases, differentiating MAS from a flare of sJIA in children [3]. While not perfectly applicable to adults without sJIA, it is the most we currently have. Given the clinical overlap between sJIA and MAS, the classification criteria may be considered to have even greater specificity in patients without sJIA, as in our patient. The classification criteria are

- (i) a fever PLUS
- (ii) ferritin levels > 684 ng/ml

and any two of the four following findings:

- platelets $\leq 181 \times 10^9/L$
- triglycerides > 156 mg/dL
- fibrinogen ≤ 360 mg/dL
- aspartate aminotransferase >48 units/L [3] (Table 2)

Treatment

Early suspicion and identification is vital in preventing mortality, though some cases will still deteriorate [29, 30]. As there are no trials for MAS, treatment protocols overlap with HLH.

The first-line treatment is similar to that of HLH. Pulse with methylprednisolone 30 mg/kg IV daily for at least 3 days [29], followed by maintenance dosing of 2–3 mg/kg/day, divided evenly into four doses over 24 hours [29]. Improvement should occur within 24–48 hours. Failure to improve after 48 hours warrants advancing to second-line treatment. Second-line treatment is parenteral cyclosporine A, dosed at 2–7 mg/kg/day [30, 31]. This should be initiated in addition to methylprednisolone, not as a substitute.

Table 2: 2016 MAS working-group criteria [2]. Our patient had both fever, and hyperferritinemia, and three out of the four secondary criteria. While these were classification criteria in children with pre-existing sJIA, our patient had no such underlying condition. Therefore, an even stronger case can be made for successful diagnosis of MAS. Our patient also met the 2004, and revised 2009 HLH diagnostic guidelines, yielding support to the interconnectedness of these diseases, with MAS being the most severe.

| 2016 MAS Classification Criteria | | | |
|----------------------------------|-------------|--------------------------------------|--------------------|
| Primary – Need both: | Medians | Secondary (2/4) | Medians |
| Fever* | | Platelets $\leq 181 \times 10^9/L^*$ | 98 $\times 10^9/L$ |
| Ferritin > 684 ng/ml* | 9,094 ng/ml | Triglycerides > 156 mg/dl | 267 mg/dl |
| | | Fibrinogen ≤ 360 mg/dl* | 220 mg/dl |
| | | AST > 48 units/L* | 171 units/L |

*indicates presence in our patient

For patients who are resistant to second line therapy, treatment can be challenging and more creative approaches are warranted. Third-line HLH-2004 treatment protocols, such as the addition of etoposide [13] may be considered. Note that myelosuppression is a side effect [13].

Antithymocyte globulin (ATG) has met with some success as a third-line treatment for MAS, especially in cases with hepato-renal disease [32]. Antithymocyte globulin is less likely to cause myelosuppression [32]. TNF and IL-1 inhibitors have also met with some success [2]. If the trigger is viral, Rituximab, in addition to immunosuppressants, has been effective for EBV-induced MAS [33].

CONCLUSION

Macrophage activation syndrome (MAS) usually occurs in pediatric populations and/or demographics with significant immune or rheumatological comorbidities making definitive diagnosis extremely difficult. As the bulk of research comes from pediatrics and hemophagocytic lymphohistiocytosis, given the clinical overlap, we must borrow when it comes to adults. While the 2016 criteria focus on differentiating macrophage activation syndrome from systemic juvenile idiopathic arthritis (sJIA), we propose that any patient meeting the classification criteria without such underlying confounders should be considered for MAS, especially given its morbidity and mortality.

Our patient is notable as an adult, developing MAS secondary to a viral trigger, without underlying identifiable rheumatological, oncological, or immunological comorbidities, which makes this case rather unique. More research is clearly needed to illuminate the pathophysiology of MAS, the relationship, even if synonymous, between Adult-Onset still's disease, hemophagocytic lymphohistiocytosis, and MAS, and address the variable treatment modalities currently considered.

Author Contributions

Luis W. Dominguez – Substantial contributions to conception and design, Acquisition of data, Analysis and interpretation of data, Drafting the article, Revising it critically for important intellectual content, Final approval of the version to be published

Valentin D. Marian – Analysis and interpretation of data, Revising it critically for important intellectual content, Final approval of the version to be published

Guarantor

The corresponding author is the guarantor of submission.

Conflict of Interest

Authors declare no conflict of interest.

Copyright

© 2017 Luis W. Dominguez et al. This article is distributed under the terms of Creative Commons Attribution License which permits unrestricted use, distribution and reproduction in any medium provided the original author(s) and original publisher are properly credited. Please see the copyright policy on the journal website for more information.

REFERENCES

1. Clementi R, Emmi L, Maccario R, et al. Adult onset and atypical presentation of hemophagocytic lymphohistiocytosis in siblings carrying PRF1 mutations. *Blood* 2002 Sep 15;100(6):2266–7.
2. Grom AA, Mellins ED. Macrophage activation syndrome: Advances towards understanding pathogenesis. *Curr Opin Rheumatol* 2010 Sep;22(5):561–6.
3. Ravelli A, Minoia F, Davi S, et al. 2016 Classification criteria for macrophage activation syndrome complicating systemic juvenile idiopathic arthritis: A European league against rheumatism/American college of rheumatology/paediatric rheumatology international trials organisation collaborative initiative. *Ann Rheum Dis* 2016 Mar;75(3):481–9.
4. Canna SW, Behrens EM. Not all hemophagocytes are created equally: Appreciating the heterogeneity of the

- hemophagocytic syndromes. *Curr Opin Rheumatol* 2012 Jan;24(1):113–8.
5. Behrens EM, Beukelman T, Paessler M, Cron RQ. Occult macrophage activation syndrome in patients with systemic juvenile idiopathic arthritis. *J Rheumatol* 2007 May;34(5):1133–8.
 6. Bae CB, Jung JY, Kim HA, Suh CH. Reactive hemophagocytic syndrome in adult-onset Still disease: Clinical features, predictive factors, and prognosis in 21 patients. *Medicine (Baltimore)* 2015 Jan;94(4):e451.
 7. Filipovich A, McClain K, Grom A. Histiocytic disorders: Recent insights into pathophysiology and practical guidelines. *Biol Blood Marrow Transplant* 2010 Jan;16(1 Suppl):S82–9.
 8. Janka G, zur Stadt U. Familial and acquired hemophagocytic lymphohistiocytosis. *Hematology Am Soc Hematol Educ Program* 2005:82–8.
 9. Otrrock ZK, Eby CS. Clinical characteristics, prognostic factors, and outcomes of adult patients with hemophagocytic lymphohistiocytosis. *Am J Hematol* 2015 Mar;90(3):220–4.
 10. Lehmborg K, Pink I, Eulenburg C, Beutel K, Maul-Pavicic A, Janka G. Differentiating macrophage activation syndrome in systemic juvenile idiopathic arthritis from other forms of hemophagocytic lymphohistiocytosis. *J Pediatr* 2013 Jun;162(6):1245–51.
 11. Ramanan AV, Baildam EM. Macrophage activation syndrome is hemophagocytic lymphohistiocytosis: Need for the right terminology. *J Rheumatol* 2002 May;29(5):1105.
 12. Stéphan JL, Zeller J, Hubert P, Herbelin C, Dayer JM, Prieur AM. Macrophage activation syndrome and rheumatic disease in childhood: A report of four new cases. *Clin Exp Rheumatol* 1993 Jul–Aug;11(4):451–6.
 13. Henter JI, Horne A, Aricò M, et al. HLH-2004: Diagnostic and therapeutic guidelines for hemophagocytic lymphohistiocytosis. *Pediatr Blood Cancer* 2007 Feb;48(2):124–31.
 14. Egües Dubuc C, Uriarte Ecnarro M, Errazquin Aguirre N, Belzunegui Otano J. Macrophage activation syndrome as a severe manifestation of adult's Still's disease. Hemophagocytic cells in ascites. [Article in English, Spanish]. *Reumatol Clin* 2014 Nov–Dec;10(6):420–1.
 15. Villanueva J, Lee S, Giannini EH, et al. Natural killer cell dysfunction is a distinguishing feature of systemic onset juvenile rheumatoid arthritis and macrophage activation syndrome. *Arthritis Res Ther* 2005;7(1):R30–7.
 16. Ménasché G, Feldmann J, Fischer A, de Saint Basile G. Primary hemophagocytic syndromes point to a direct link between lymphocyte cytotoxicity and homeostasis. *Immunol Rev* 2005 Feb;203:165–79.
 17. Larroche C, Mouthon L. Pathogenesis of hemophagocytic syndrome (HPS). *Autoimmun Rev* 2004 Feb;3(2):69–75.
 18. Arceci RJ. When T cells and macrophages do not talk: The hemophagocytic syndromes. *Curr Opin Hematol* 2008 Jul;15(4):359–67.
 19. Kägi D, Odermatt B, Mak TW. Homeostatic regulation of CD8+ T cells by perforin. *Eur J Immunol* 1999 Oct;29(10):3262–72.
 20. Aricò M, Janka G, Fischer A, et al. Hemophagocytic lymphohistiocytosis. Report of 122 children from the International Registry. FHL Study Group of the Histiocyte Society. *Leukemia* 1996 Feb;10(2):197–203.
 21. Trottestam H, Horne A, Aricò M, et al. Chemoimmunotherapy for hemophagocytic lymphohistiocytosis: Long-term results of the HLH-94 treatment protocol. *Blood* 2011 Oct 27;118(17):4577–84.
 22. Ramos-Casals M, Brito-Zerón P, López-Guillermo A, Khamashta MA, Bosch X. Adult haemophagocytic syndrome. *Lancet* 2014 Apr 26;383(9927):1503–16.
 23. Stapp J, Wilkerson S, Stewart D, Coventry S, Mo JQ, Bove KE. Fulminant neonatal liver failure in siblings: probable congenital hemophagocytic lymphohistiocytosis. *Pediatr Dev Pathol* 2006 May–Jun;9(3):239–44.
 24. Palazzi DL, McClain KL, Kaplan SL. Hemophagocytic syndrome in children: An important diagnostic consideration in fever of unknown origin. *Clin Infect Dis* 2003 Feb 1;36(3):306–12.
 25. Okamoto M, Yamaguchi H, Isobe Y, et al. Analysis of triglyceride value in the diagnosis and treatment response of secondary hemophagocytic syndrome. *Intern Med* 2009;48(10):775–81.
 26. Bode SF, Lehmborg K, Maul-Pavicic A, et al. Recent advances in the diagnosis and treatment of hemophagocytic lymphohistiocytosis. *Arthritis Res Ther* 2012 Jun 8;14(3):213.
 27. Ohadi M, Lalloz MR, Sham P, et al. Localization of a gene for familial hemophagocytic lymphohistiocytosis at chromosome 9q21.3–22 by homozygosity mapping. *Am J Hum Genet* 1999 Jan;64(1):165–71.
 28. Filipovich AH. Hemophagocytic lymphohistiocytosis (HLH) and related disorders. *Hematology Am Soc Hematol Educ Program* 2009:127–31.
 29. Stéphan JL, Koné-Paut I, Galambrun C, Mouy R, Bader-Meunier B, Prieur AM. Reactive haemophagocytic syndrome in children with inflammatory disorders. A retrospective study of 24 patients. *Rheumatology (Oxford)* 2001 Nov;40(11):1285–92.
 30. Ravelli A, Grom AA, Behrens EM, Cron RQ. Macrophage activation syndrome as part of systemic juvenile idiopathic arthritis: Diagnosis, genetics, pathophysiology and treatment. *Genes Immun* 2012 Jun;13(4):289–98.
 31. Ravelli A, De Benedetti F, Viola S, Martini A. Macrophage activation syndrome in systemic juvenile rheumatoid arthritis successfully treated with cyclosporine. *J Pediatr* 1996 Feb;128(2):275–8.
 32. Coca A, Bundy KW, Marston B, Huggins J, Looney RJ. Macrophage activation syndrome: Serological markers and treatment with anti-thymocyte globulin. *Clin Immunol* 2009 Jul;132(1):10–8.
 33. Balamuth NJ, Nichols KE, Paessler M, Teachey DT. Use of rituximab in conjunction with immunosuppressive chemotherapy as a novel therapy for Epstein Barr virus-associated hemophagocytic lymphohistiocytosis. *J Pediatr Hematol Oncol* 2007 Aug;29(8):569–73.

Access full text article on
other devices



Access PDF of article on
other devices

